Case Report

DOI: 10.7860/IJNMR/2026/91476.2494

Paediatrics Section

Incontinentia Pigmenti (IKBKG Exon 4-10 Deletion): A Neonatal Case Report with Multisystem Involvement

K BAVITHRA[1], NANDINI VASUDEVAN[2], UMAMAHESWARI BALAKRISHNAN[3], RANJITH KUMAR[4], NISHANTH RAJAN[5]

BY-NC-ND

ABSTRACT

Incontinentia Pigmenti (IP) is an X-linked dominant disorder with neurocutaneous manifestations caused by IKBKG gene. The clinical course includes four stages including eye and neurocutaneous findings. Recurrent deletions involving IKBKG gene in 4-10 exons result in severe phenotypes. The present report is of a female neonate who presented with vesiculobullous lesions at birth which evolved to erythematous hyperpigmented whorled lesions which were distributed along Blaschko lines. On Day 3 of life, baby developed seizures and had poor activity. Neuroimaging revealed multifocal intraparenchymal and intraventricular haemorrhages with early cystic degeneration. Ophthalmologic findings include retinal haemorrhages and peripheral ischaemic changes. Whole exome sequencing confirmed a heterozygous deletion of IKBKG exons 4-10. Despite maximal efforts and multidisciplinary care, infant had progressive neurological deterioration and succumbed to death. Early recognition of these characteristic patterns, might have prompted systemic evaluation and genetic confirmation. Recurrent exon deletion in IKBKG genes is associated with severe phenotype with multisystem involvement.

Keywords: Blaschko lines, Cerebral vasculopathy, Neonatal seizures, Retinal non perfusion, X-linked inheritance

CASE REPORT

A 3.16-kg female neonate was born at 37 weeks + 4 days of gestation by elective lower-segment caesarean section to a 39-year-old G2P1L1 mother. First born was male child, alive and healthy. The pregnancy was complicated by overt diabetes mellitus and chronic hypertension. At 22 weeks of gestation, the mother had developed grouped vesicular lesions over the nape of the neck, for which she was treated with oral acyclovir. There was no history of consanguinity, known genetic disorders, or unexplained neonatal deaths in the family. The neonate had no significant antenatal or perinatal complications apart from those mentioned.

At birth, multiple erythematous vesiculobullous and pustular lesions containing serous fluid were noted over the trunk and extremities, with sparing of the palms, soles, and mucosa [Table/Fig-1]. Over the subsequent 48-72 hours, new lesions appeared with partial crusting and subsequently evolved into hyperpigmented, whorled and linear lesions following the Blaschko lines [Table/Fig-2]. Based on the characteristic evolution of the skin lesions, the provisional diagnosis of IP was considered, with neonatal Herpes Simplex Virus (HSV) infection as an important differential diagnosis.

On the third day of life, the infant developed lethargy, poor feeding, and recurrent focal and generalised seizures, which progressed to refractory status epilepticus. Neurological examination revealed variable tone with brisk deep tendon reflexes. A Tzanck smear of the skin lesions demonstrated eosinophils, favouring IP, while HSV and varicella Polymerase Chain Reaction (PCR) were negative. Complete blood count, serum electrolytes, liver and renal function tests, septic evaluation, Cerebrospinal Fluid (CSF) analysis and culture were initially within normal limits, and tandem mass spectrometry screening was negative. Cranial ultrasonography demonstrated intraventricular echoes suggestive of haemorrhage with periventricular echogenic changes. Fundus examination revealed bilateral retinal haemorrhages and peripheral retinal non perfusion/ischaemic changes. In view of the characteristic skin lesions, neurological deterioration and retinal abnormalities, IP with multisystem involvement was strongly suspected. As advanced neuroimaging and molecular genetic testing were not available at the initial referring centre, the parents were counselled regarding the need for further evaluation at a higher centre and the infant was referred/transferred for further management.



[Table/Fig-1]: Clinical photograph of the neonate.



[Table/Fig-2]: Pattern of skin lesion along blaschko's line.

Magnetic Resonance Imaging (MRI) brain with magnetic resonance spectroscopy performed at the higher centre demonstrated multifocal areas of diffusion restriction with microbleeds involving the bilateral cerebral hemispheres, predominantly the white matter along the corticospinal tracts, basal ganglia and right cerebellar hemisphere [Table/Fig-3], findings consistent with IP-associated cerebral vasculopathy.

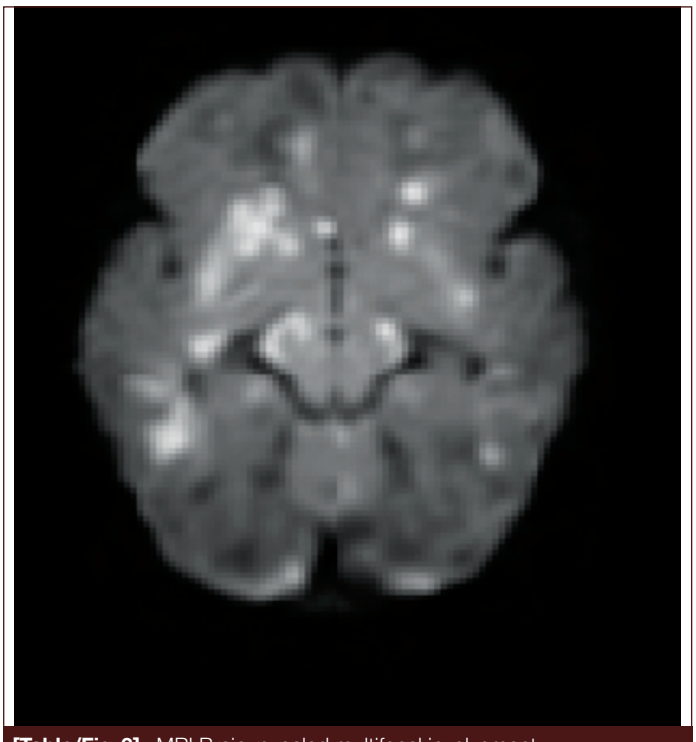

[Table/Fig-3]: MRI Brain revealed multifocal involvement.

The infant required intensive care for refractory seizures and was electively intubated and treated with continuous midazolam infusion along with phenobarbitone, levetiracetam and phenytoin; empirical pyridoxine, biotin and folinic acid were also administered. The retinal abnormalities were documented and monitored; however, anti-VEGF therapy or laser photocoagulation was not performed, as the infant developed rapidly progressive neurological and systemic deterioration and there was no documented neovascularisation or retinal detachment during the short period of observation.

On the seventh day of life, the infant developed oliguria, severe hyperkalaemia and refractory metabolic acidosis requiring peritoneal dialysis, together with shock requiring inotropic and vasopressor support. Despite maximal multidisciplinary supportive care, the neurological status progressively deteriorated and the infant developed refractory shock, resulting in death on the eighth day of life.

In view of the characteristic cutaneous, neurological and ophthalmological findings, molecular genetic testing was subsequently performed at the higher centre and demonstrated a heterozygous pathogenic deletion involving exons 4-10 of the IKBKG gene [Table/Fig-4], confirming the diagnosis of IP. Both parents were found to be homozygous normal and the affected baby has a de novo heterozygous 11.7 kb deletion involving IKBKG exon 4-10.

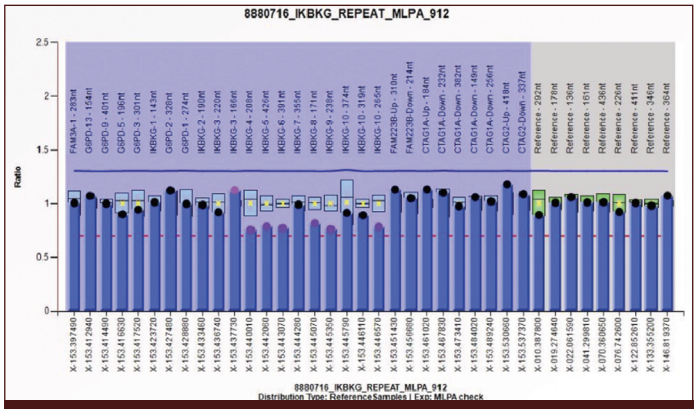

[Table/Fig-4]: 8880716_MLPA Ratio Chart: IKBKG.

The mother and family were counselled regarding the X-linked dominant inheritance of IP and the recurrence risk in future pregnancies, including the possibility of variable clinical expression in female offspring and severe or non viable disease in male offspring. The option of prenatal diagnosis and preimplantation genetic testing in future pregnancies was also discussed. Parental testing has been done and both parents were found to be homozygous normal and the affected baby has a de novo heterozygous 11.7 kb deletion involving IKBKG exon 4-10. The final diagnosis was therefore IP with severe multisystem involvement, including cutaneous, cerebral and retinal vasculopathy, associated with a pathogenic IKBKG exon 4-10 deletion which was de novo.

DISCUSSION

The IP, also known as Bloch-Sulzberger syndrome, is a rare neurocutaneous disorder with a genetic basis that is transmitted on the X chromosome (Xq28). IKBKG encodes NEMO, which is an important regulator of the NF-κB pathway. In the current neonate, the diagnosis was confirmed by a heterozygous deletion of exons 4-10 of IKBKG, which leads to abnormal apoptosis and inflammation and accounts for the multisystem presentation of IP [1]. The skin lesions were also typical demonstrating vesiculobullous and pustular lesions at birth that later crust and become linear hyperpigmentation along Blaschko lines. The results are consistent with the initial phase of IP. In such instances, the clinical presentation may have been confused with HSV or varicella or bacterial infection and PCR testing of HSV and varicella were negative, combined with eosinophils on Tzanck

smear, characteristic lesion evolution, and ultimately genetic testing confirmed IP [1,2]. A negative family history is not contraindication, as there are sporadic cases [3].

Severe neurological involvement was the major feature in this neonate. On the third day of life, the baby was becoming lethargic, poor feeders, with focal and generalised seizures, and refractory status epilepticus. MRI revealed multifocal diffusion restriction and microbleeds in the cerebral hemispheres, corticospinal tracts, basal ganglia and cerebellum. A more recent study done by Yin L et al., of 41 children with IP reported cerebral ischaemia, hypoperfusion, haemorrhage, encephalomalacia, and cerebral atrophy in the children, which was consistent with the spectrum of cerebrovascular abnormalities observed in this case [4]. The combination of multifocal ischaemic and haemorrhagic lesions was consistent with IP-associated small-vessel vasculopathy and may not follow a single arterial territory. Similar severe cerebrovascular abnormalities and rapid neurological deterioration have been reported in neonatal IP [5,6]. The normal metabolic screening, CSF analysis, cultures, and TMS screening further reduced the likelihood of infectious or metabolic causes of neonatal encephalopathy.

Additional evidence of systemic vascular involvement was obtained from the ocular findings. There were bilateral retinal haemorrhages and peripheral retinal non perfusion in the infant. The abnormalities found in the retina in IP consist of avascularisation in the peripheral retina, vascular abnormalities, haemorrhage, neovascularisation, and retinal detachment. Studies have shown that there is a correlation between retinal involvement and CNS involvement, and that generalised IP-associated vasculopathy exists, suggesting the need to assess early in the eye and perform broad retinal evaluation in patients with involvement of the CNS [7,8]. It was of special interest that the molecular deletion of IKBKG exon 4-10 was discovered. In this case, gene-specific methods were described in recent molecular studies to detect this deletion, which is difficult to identify due to the presence of the highly homologous IKBKG pseudogene and was essential to make the diagnosis as there was no known family history. Study conducted by Steffann J et al., on two sisters from different parental lineages showed two different de novo pathogenic variants in the IKBKG gene [9]. Although recurrence of independent de novo IKBKG variants within the same family is rare, residual recurrence risk due to germline mosaicism may be considered where the familial pathogenic variant is known [9].

This case represents the severe end of the IP spectrum, characterised by rapid clinical deterioration and early mortality. Although septic shock, acute kidney injury, hyperkalaemia, and metabolic acidosis contributed to the terminal deterioration, severe neurological involvement was evident as early as day 3 of life. Recent reports have also highlighted substantial neurological morbidity among patients with IP and central nervous system involvement [5,6].

CONCLUSION(S)

This case highlights the importance of the clinical diagnosis in the neonate with vesiculobullous or pustular lesions that occurred along Blaschko lines, which included the possibility of IP among others. A number of the key signs for suspicions are neurological signs, retinal problems and unexplained brain lesions. Specific lesions can be identified by MRI and early eye examinations can detect non perfusion in the retina. In atypical cases genetic testing is essential for appropriate family counselling. Overall the case presents a very severe phenotype of IP, requiring a full multisystem assessment.

Author contribution: Dr. Bavithra and Dr. Nandhini. V has managed the case under guidance of our unit chief Dr. Nishanth. R. Baby has been referred to SRMC, for further management under Dr. Uma (Neonatologist) and Dr. Ranjith Kumar (Pediatric neurologist). Dr. Nandhini has left institution (PIMS) and joined Manipal hospital for her higher studies.

REFERENCES

[1] How KN, Leong HJY, Pramono ZAD, Leong KF, Lai ZW, Yap WH. Uncovering incontinentia pigmenti: From DNA sequence to pathophysiology. Front Pediatr. 2022;10:900606. Doi: 10.3389/fped.2022.900606.

[2] Rosser T. Incontinentia pigmenti. Semin Pediatr Neurol. 2024;51:101156. Doi: 10.1016/j.spen.2024.101156.

[3] Yuan F, Zhu FN, Liu XJ, Li J, Xu HT. Incontinentia pigmenti: A case report of early clinical symptoms in a lack of family inheritance positive result. Clin Cosmet Investig Dermatol. 2023;16:1209-14. Doi: 10.2147/CCID.S407506.

[4] Yin L, Li Z, Zhan W, Kang Y, Tian Q, Li D, et al. Central nervous system anomalies in 41 Chinese children incontinentia pigmenti. BMC Neurosci. 2024;25:25. Doi: 10.1186/s12868-024-00872-1.

[5] Lin X, Zhang W, Zhou P. A case report of neonatal incontinentia pigmenti complicated by severe cerebrovascular lesions in one of the male monozygotic twins. Front Pediatr. 2024;12:1338054. Doi: 10.3389/fped.2024.1338054.

[6] Li Y, Hong J, Xu S, Zhou T, Xiao X, Yang J, et al. Case report: Diagnosis and treatment of incontinentia pigmenti with central nervous system anomalies in one patient. Front Pediatr. 2024;12:1490816. Doi: 10.3389/fped.2024.1490816.

[7] Danford ID, Scruggs BA, Capone A Jr, Trese MT, Drenser KA, Thanos A, et al. The prevalence of retinal disease and associated CNS disease in young patients with incontinentia pigmenti. Ophthalmol Retina. 2022;6(12):1113-21. Doi: 10.1016/j.oret.2022.05.032.

[8] Rai RS, Li AS, Ferrone PJ. Ophthalmologic presentations of incontinentia pigmenti. J Vitreoretin Dis. 2024;8(2):186-91. Doi: 10.1177/24741264241227680.

[9] Steffann J, De Oliveira Santos J, Zelbin AL, Hadj-Rabia S, Charbit-Henrion F, Petit F. Familial recurrence of incontinentia pigmenti due to de novo pathogenic variants in the IKBKG gene. Am J Med Genet A. 2024;194(8):e63591. Doi:10.1002/ajmg.a.63591. Epub 2024 Mar 27. PMID: 38536952.

PARTICULARS OF CONTRIBUTORS:

1. Junior Resident, Department of Paediatrics, Pondicherry Institute of Medical Sciences, Kalapet, Pondicherry, India.
2. Assistant Professor, Department of Paediatrics, Manipal Hospitals, Old Airport Road, Bangalore, India.
3. Professor, Department of Neonatology, SRMC, Porur, Tamil Nadu, India.
4. Associate Professor, Department of Paediatric Neurology, SRMC, Porur, Tamil Nadu, India.
5. Professor, Department of Paediatrics, Pondicherry Institute of Medical Sciences, Kalapet, Pondicherry, India.

NAME, ADDRESS, E-MAIL ID OF THE CORRESPONDING AUTHOR:
Dr. Nishanth Rajan,
Professor, Department of Paediatrics, PIMS Hospital, Kalapet-605014, Pondicherry, India.
E-mail: nishanthwolverine@gmail.com

PLAGIARISM CHECKING METHODS: [Jain H et al.]

- Plagiarism X-checker: Jun 26, 2026
- Manual Googling: Oct 05, 2026
- iThenticate Software: Oct 09, 2026 (2%)

ETYMOLOGY: Author Origin

EMENDATIONS: 6

AUTHOR DECLARATION:

- Financial or Other Competing Interests: None
- Was informed consent obtained from the subjects involved in the study? Yes
- For any images presented appropriate consent has been obtained from the subjects. Yes

Date of Submission: **Jun 24, 2026**
Date of Peer Review: **Sep 05, 2026**
Date of Acceptance: **Oct 10, 2026**
Date of Publishing: **Dec 31, 2026**